



Dr. Paul Harch, President 504-348-1660 [www.hyperbarics.org](http://www.hyperbarics.org)  
Ken Locklear, Executive Director 561-640-4546 [www.hbomedtoday.com/dbsearch.html](http://www.hbomedtoday.com/dbsearch.html)

Presentation prepared by Anita Poole CPS/CAP

LHE May 02, 2002  
Copyright Retained  
Paul G. Harch, M.D. 2002



## Hyperbaric Oxygen Therapy and SPECT Brain Imaging in the Treatment of Chronic Brain Injury

*Paul G. Harch, M.D.  
Clinical Assistant Professor L.S.U. School of Medicine*

- Refined low-pressure Hyperbaric Oxygen Therapy (HBOT) protocols for neurological injuries.
- Presentation includes selective sampling of nearly 400 chronic brain injuries over the past 12 years.
- Original case was demented diver with residual brain decompression sickness 7 months after injury.
  - Diver achieved clinical, psychometric, & functional brain imaging improvement.
- Discovery then generalized to patients with:
  - \* Chronic traumatic brain injury.
  - \* Cerebral palsy.
  - \* Chronic carbon monoxide poisoning.
  - \* Toxic brain injury.
  - \* Chronic stroke.
  - \* Alzheimer's Disease.
  - \* Autism.
  - \* Substance abuse.
  - \* 30 other neurological conditions.
- After demonstrating effectiveness in humans, a 1996 and 2001 animal study demonstrated the first ever improvement in chronic brain injury.
- Treatment protocol developed by Dr. Harch now being used in research/clinical practices by multiple centers throughout the United States and internationally.
- World-wide experience has demonstrated the generic rehabilitative potential of low pressure HBOT in chronic brain and neurological injury.

LHE May 02, 2002  
Copyright Retained  
Paul G. Harch, M.D. 2002



## Case Presentation

### *Triple head SPECT Scan of Normal Brain*

*SPECT is a tool to directly measure brain blood flow and indirectly measure metabolism.*

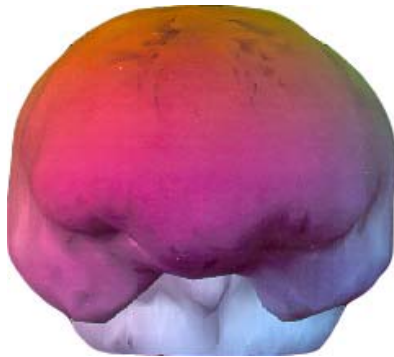
- 26 year old female (left scan).
- 34 year old male (right scan).
- No alcohol or substance abuse.
- No brain traumas.
- No diseases to affect brain blood flow or metabolism.
- Notice smooth appearance.

LHE May 02, 2002  
Copyright Retained  
Paul G. Harch, M.D. 2002




## Case Presentation

### *Triple head SPECT Scan of Normal Brain*



female



male

LHE May 02, 2002  
Copyright Retained  
Paul G. Harch, M.D. 2002



# Case Presentation

## *Acute & Chronic Treatment of Traumatic Brain Injury and Coma*

- 19 year old male; college freshman. Ejected from motor vehicle at 65 mph in 1991 (1<sup>st</sup> HBOT began 19 hours post accident).
- Impacted left frontal/parietal skull region.
  - Within ½ hour Glasgow coma scale was 6-7, ventilator dependent.
  - CT revealed diffuse edema, midline shift, petechial hemorrhages, subarachnoid hemorrhage, small subdural hematoma, basilar skull fracture.
- 1<sup>st</sup> scan: SPECT image 1 month after accident shows significant injury to left frontal area and contra coup injury to right parietal/occipital with luxury perfusion.
  - Scan shows very large defects in brain blood flow.
- After initial treatments patient became conversant & independently ambulatory with slight spasticity.
- Within 8 weeks of accident patient went from ventilator to walking and talking.

LHE May 02, 2002  
Copyright Retained  
Paul G. Harch, M.D. 2002



# Case Presentation

## *Acute & Chronic Treatment of Traumatic Brain Injury and Coma (continued)*

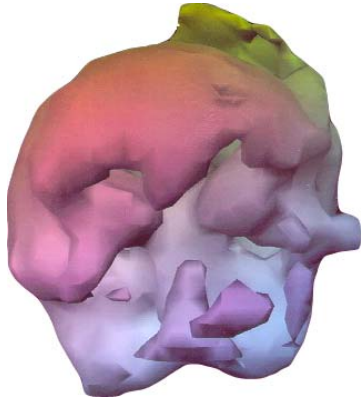
- 2<sup>nd</sup> scan: 1 year later after 188 HBOT treatments.
  - Improved perfusion in ischemic penumbral areas of right-sided lesions.
  - Noticeable improvement in cognition (40% gain written computation math).
  - Patient verbalized insight to condition and that he could no longer aspire to be a surgeon.
  - Balance and gait improvement from 3-wheel trike to 2-wheel bike.
- Treatments discontinued when patient enrolled in remedial college courses.
- Patient referred to as "Lazarus" by his doctor.
- In Jan. 2001, 12 years post injury, patient called physician to tell him of 2<sup>nd</sup> promotion at the bank. Patient active, functional, and employed.
- Current cost of 188 HBOT treatments at \$150-\$200 each: **\$28,200-\$37,600**
  - Note: treatment during immediate acute phase of injury could cost more.

LHE May 02, 2002  
Copyright Retained  
Paul G. Harch, M.D. 2002

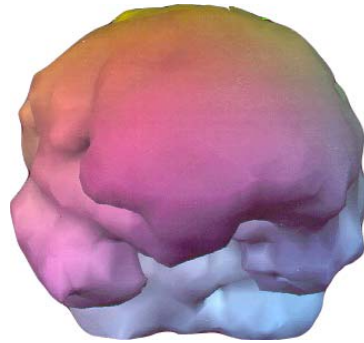


# Case Presentation

*Acute & Chronic Treatment of Traumatic Brain Injury and Coma*  
19 y. male



Scan #1



Scan #2

LHE May 02, 2002  
Copyright Retained  
Paul G. Harch, M.D. 2002



**See previous page for case history on this patient.**

LHE May 02, 2002  
Copyright Retained  
Paul G. Harch, M.D. 2002



# Case Presentation

## *Traumatic Brain Injury and Substance Abuse*

- 23 year old male, Navy Medical Corpsman, graduated second in class.
- 5 TBIs; (4 w/loss of consciousness) the 3<sup>rd</sup> resulted in largest loss of memory and started migraines.
- Complaints of migraines, short & long-term memory loss, speech problems, serious alcohol abuse. Treated at Bethesda and Walter Reed Brain Injury Center.
  - Discharged from Navy with 60% VA disability.
- Unable to remember anatomy and physiology during rehab training; 14 jobs in 2 years.
  - 1<sup>st</sup> scan: Extensive frontal lobe injury & top scan shows extensive tissue damage.
- Jan. 2001: 40 HBOT treatments over 4 weeks.
  - 2<sup>nd</sup> scan: Extensive improvement in blood flow to frontal & parietal lobes.
- Dramatic cessation of migraine headaches.
  - Cessation of marijuana use & dramatic reduction in alcohol use.
- 1 month after treatments: Return of memory, tremendous improvement in speech, cognition, math skills, and energy levels.
- 8 months after treatment: Married & remains functional to date; patient to return for additional HBOTs.

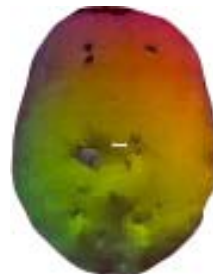
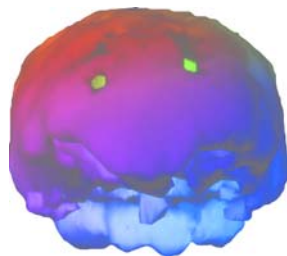
LHE May 02, 2002  
Copyright Retained  
Paul G. Harch, M.D. 2002



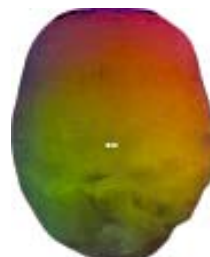

# Case Presentation

## *Traumatic Brain Injury and Substance Abuse* *23 y. male*

Scan #1



Scan #2



LHE May 02, 2002  
Copyright Retained  
Paul G. Harch, M.D. 2002



# Case Presentation

## *Traumatic Brain Injury*

- 23 year old female.
- 5 ½ years post motor vehicle accident; major TBI & ventilation for 3 weeks.
- Complaints of aphasia, left body weakness with spasticity, cognitive problems w/generalized decrease in intellectual capacity, emotional instability, mood swings & temper tantrums post injury.
- Prior to HBOT: Innumerable therapies with no resolution of problems.
  - 1<sup>st</sup> scan: Marked reduction in flow to right temporal lobe.  
Marked decrease in parasagittal regions of brain.  
Surface texture very coarse (heterogeneous blood flow).
- 80 HBOT treatments.
  - 2<sup>nd</sup> scan: Shows greatly improved brain blood flow.
    - Improvement in left body paresis/imbalance.
    - Temper tantrums/mood swings noticeably decreased.
    - Ability to read/write substantially improved.
    - Marked improvement in physical endurance.

LHE May 02, 2002  
Copyright Retained  
Paul G. Harch, M.D. 2002

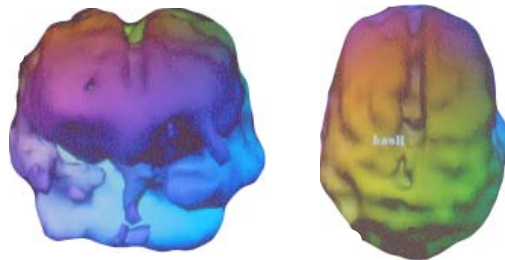


# Case Presentation

## *Traumatic Brain Injury*

*23 y. female*

Scan #1



Scan #2

LHE May 02, 2002  
Copyright Retained  
Paul G. Harch, M.D. 2002



# Case Presentation

## *Alzheimer's Disease*

- 58 year old male.
- Accomplished architect with decline in work & memory 8 years ago.
- Alzheimer's diagnosis 5½ years ago; started on Aricept.
  - Continued to decline over next 3 years. Started CPAP (for sleep apnea) 9/98 without effect 3 years prior to HBOT treatments.
  - Switched to Neotrophin for 9 months – limited improvement.
  - 9/2000 began Exelon; dose increased to maximum level 6 weeks before HBOT.
    - Wife notes improvement in cognition & behavior.
- 89 HBOT treatments.
  - During treatment progressive slow improvement in cognition/behavior.
  - Generalized non significant improvement in scores.
  - Some new learning ability.
  - Symptomatically patient better.
  - Patient taken off Exelon due to side effects.
  - Continuing HBOT & beginning to resume normal life activities.

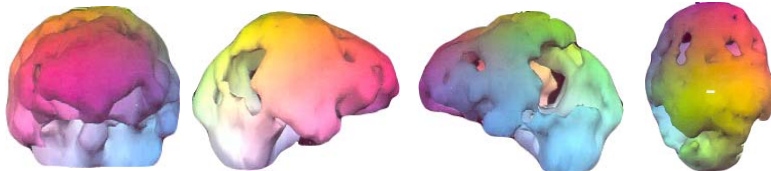
LHE May 02, 2002  
Copyright Retained  
Paul G. Harch, M.D. 2002



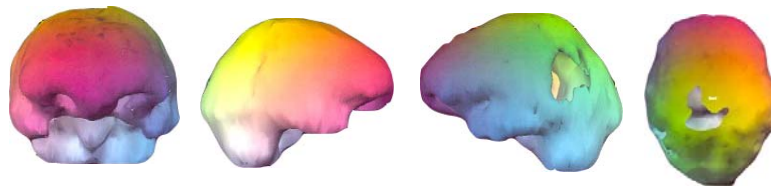
# Case Presentation

## *Alzheimer's Disease* 58 y. male

Baseline



After  
89 HBOT  
Treatments



LHE May 02, 2002  
Copyright Retained  
Paul G. Harch, M.D. 2002



# Case Presentation

## *Physical Abuse*

- 21 year old female, gang raped and beaten extensively at age 12.
- Significant cognitive deficit though apparently normal motor coordination.
  - Severe difficulties with sleep.
    - 1<sup>st</sup> scan: SPECT shows significant frontal lobe injury with severe frontal lobe tissue damage.
- 60 HBOT treatments.
  - 2<sup>nd</sup> scan: SPECT shows greatly increased blood flow to frontal lobe manifested by thickening & filling in on scan.
- Improved cognitive function enables patient to operate in a higher capacity in a mentally demanding job.
- Patient promoted 6 months post treatment.
  - Sleep difficulties improved.


LHE May 02, 2002  
Copyright Retained  
Paul G. Harch, M.D. 2002



# Case Presentation

## *Physical Abuse*

*21 y. female*



Scan #1



Scan #2

LHE May 02, 2002  
Copyright Retained  
Paul G. Harch, M.D. 2002





# Case Presentation

## *Mental Retardation*

- 44 year old male. Mentally retarded from likely combination of delivery-induced trauma and TBI at 2 weeks old.
- Unable to read or spell more than a few words. No abstract reasoning ability. Difficulty understanding concepts, i.e., food will spoil if left out.
- Seizures bi-weekly with constant tremors; on medication. Worked 2 days/week at Goodwill doing menial tasks.
  - 1<sup>st</sup> scan: SPECT shows reduction in blood flow to frontal lobe (extensive frontal lobe damage).
- 40 HBOT treatments.
  - 2<sup>nd</sup> scan: SPECT shows a marked increase in blood flow in the frontal lobe, manifest by closure of fissures.
- Work attendance from 2 days to 4 days per week.
- Seizure rate fell to 1 per month on medication. Noticeable reduction in motor tremors.
- Presently learning to read at a Kindergarten level.
- Able to understand abstract concepts better, i.e., that food spoils.
- Able to do more complex work tasks. Increased rational behavior.

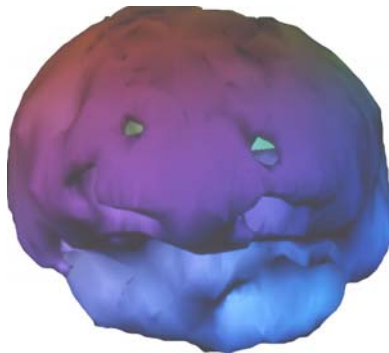
LHE May 02, 2002  
Copyright Retained  
Paul G. Harch, M.D. 2002



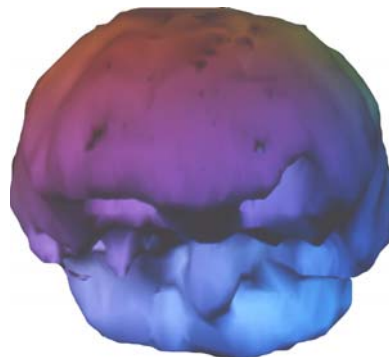
# Case Presentation

## *Mental Retardation*

*44 y. male*



Scan #1



Scan #2

LHE May 02, 2002  
Copyright Retained  
Paul G. Harch, M.D. 2002



# Case Presentation

## *Cerebral Palsy*

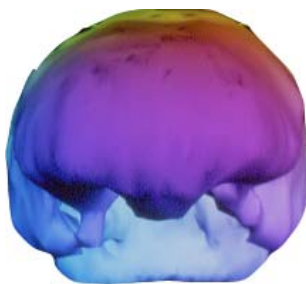
- 8 year old boy.
- Complicated, difficult delivery resulted in ischemic hypoxic injury to brain.
  - 1<sup>st</sup> scan: Prominent abnormalities in temporal lobes, especially on left side.
  - 2<sup>nd</sup> scan: Generalized improvement in blood flow with greater amount of yellow on the slices on far right of picture.
    - Improved flow to both temporal lobes.
- Patient's mother reported:
  - Some improvement in inappropriate behavior.
  - Less leg dragging.
  - Markedly improved ability to have bowel movements with no incontinence.
  - Muscle tone, attention, concentration improvements.

LHE May 02, 2002  
Copyright Retained  
Paul G. Harch, M.D. 2002




# Case Presentation

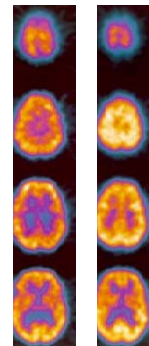
## *Cerebral Palsy* *8 y. male*



Scan #1



Scan #2



#1

#2

LHE May 02, 2002  
Copyright Retained  
Paul G. Harch, M.D. 2002



# Case Presentation

## *Stroke*

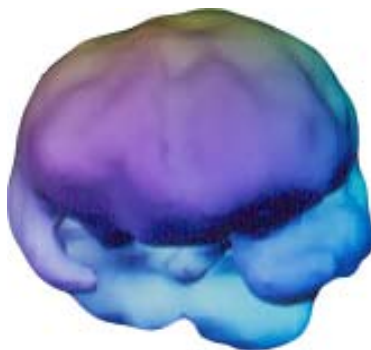
- 60 year old male. 2 years post stroke.
- History of multiple white matter strokes.
- Complaints of body weakness, intractable dizziness, difficulty swallowing, speech problems.
  - 1<sup>st</sup> scan: Surface of brain with coarse texture & markedly decreased blood flow in right temporal lobe.
- 80 HBOT treatments.
  - 2<sup>nd</sup> scan: Improvement in coarse texture & greatly increased blood flow.
- Dizziness reduced to point that patient could:
  - Leave house.
  - Walk without cane.
  - Stopped using left knee brace.
  - Speech & swallowing improved.
  - Overall mood improved.

LHE May 02, 2002  
Copyright Retained  
Paul G. Harch, M.D. 2002

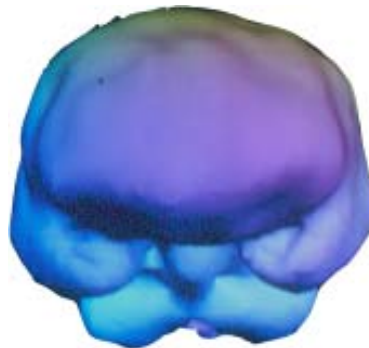


# Case Presentation

## *Stroke 60 y. male*



Scan #1



Scan #2

LHE May 02, 2002  
Copyright Retained  
Paul G. Harch, M.D. 2002



# Case Presentation

## *Alcoholism and Stroke*

- 68 year old male. 1 month post embolic stroke right middle cerebral artery.
- Chronic heavy drinker. Developed atrial fibrillation, likely secondary to the alcohol.
- Severe weakness left side of body; profound left-sided neglect.
  - Noticeable cognitive deterioration (power of attorney to son).
- 1<sup>st</sup> scan: Multiple areas of decreased perfusion in frontal & temporal lobes.
  - Slightly coarse appearance to brain surface. Note large gap on left side of each image denoting right hemispheric stroke.
- 1 month of HBOT treatments:
  - Dramatic improvement in cognition, speed of thinking, decrease in neglect.
  - Markedly improved motor function on left side of body.
  - Rescinded power of attorney & resumed active pursuit of business affairs.
- 2<sup>nd</sup> scan: Improved flow to all lobes. Global smoothing of brain surface.

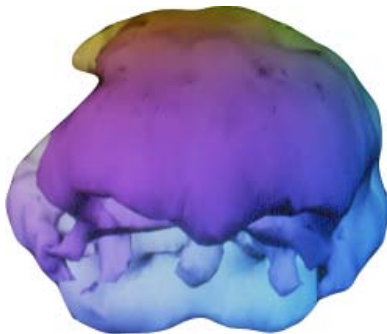
LHE May 02, 2002  
Copyright Retained  
Paul G. Harch, M.D. 2002



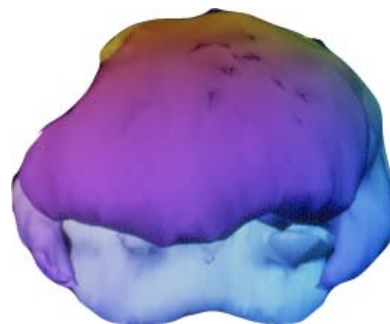
# Case Presentation

## *Alcoholism and Stroke*

*68 y. male*



Scan #1



Scan #2

LHE May 02, 2002  
Copyright Retained  
Paul G. Harch, M.D. 2002



# Case Presentation

## Substance Abuse

- 19 year old male. Extensive drug abuse history for past 4 years (since 15).
  - Heavy dosing, chronic marijuana.
  - LSD & 5-6 episodes of hallucinogenic mushrooms.
  - Extensive Rohypnol use (patient believes caused most memory problems).
  - Cocaine, crack abuse for 1 month earlier in year of 1<sup>st</sup> brain scans.
  - Extensive use of Valium.
  - Concentrated glue sniffing & White Out typewriter correction solvent.
  - Alcohol abuse.
- Complaints of chronic headaches, irritability, impulsive behavior, and short-term memory problems.
- History of loss of consciousness in the past due to trauma and an episode of syncope that same year; 5 years before 1<sup>st</sup> first brain scan.
  - 1<sup>st</sup> scan: Grossly heterogeneous pattern of brain blood flow with multiple areas of decreased perfusion in frontal and temporal lobes.
  - 2<sup>nd</sup> scan: 1 HBOT. Global smoothing & improvement in blood flow. Inferior frontal lobe defects likely due to patient's trauma. **Note: Single HBOT improvement is predictive that the full course of HBOT treatment (40 HBOTs minimum for treatment of a chronic injury) would permanently improve the patient's brain and brain function.**
- Patient did limited course of 20 HBOTs, then defaulted on treatments due to feeling better and the 200 mile commute.

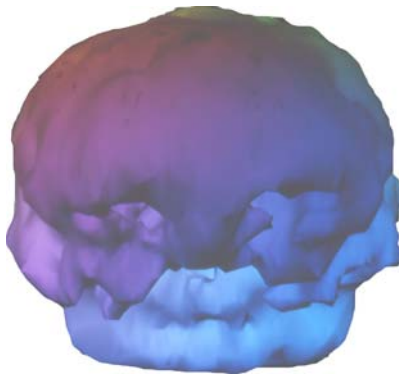
LHE May 02, 2002  
Copyright Retained  
Paul G. Harch, M.D. 2002



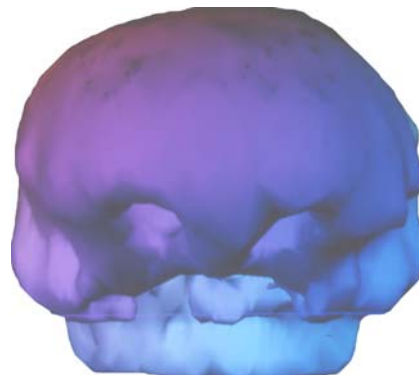
# Case Presentation

## Substance Abuse

19 y. male



Scan #1



Scan #2

LHE May 02, 2002  
Copyright Retained  
Paul G. Harch, M.D. 2002



# Case Presentation

## *Carbon Monoxide Poisoning*

- 51 year old female.
- Exposed to home gasoline powered generator in poorly ventilated area.
- Complaints of headaches, trouble thinking, walking, talking, functioning, increasingly somnolent & confused. Diagnosed with altered mental status.
- At 36 hours blood carboxyhemoglobin elevated at 2.2% (upper limits of normal, 1.5%).
  - 1<sup>st</sup> scan: Pattern very coarse with multiple significant deficits in blood flow.
- 1 HBOT 68 hours after admission at 2 atms for 35 mins (patient claustrophobic).
  - 2<sup>nd</sup> scan: 3 hours later
    - Dramatic improvement in brain blood flow.
    - Smoothing of the overall pattern.
    - Noticeable improvement in mental and cognitive status.

LHE May 02, 2002  
Copyright Retained  
Paul G. Harch, M.D. 2002

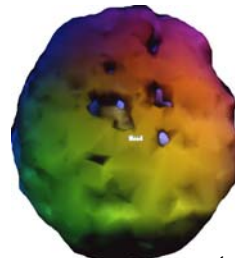
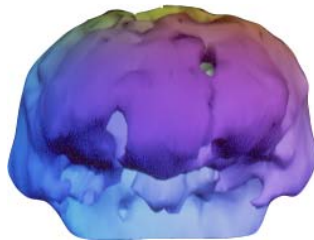


# Case Presentation

## *Carbon Monoxide Poisoning*

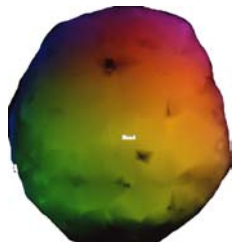
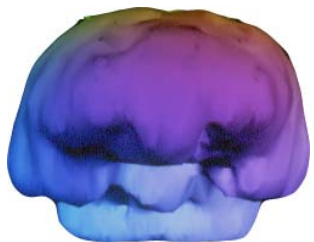
*51 y. female*

Scan #1



top view

Scan #2



LHE May 02, 2002  
Copyright Retained  
Paul G. Harch, M.D. 2002



# Case Presentation

## *Shaken Baby*

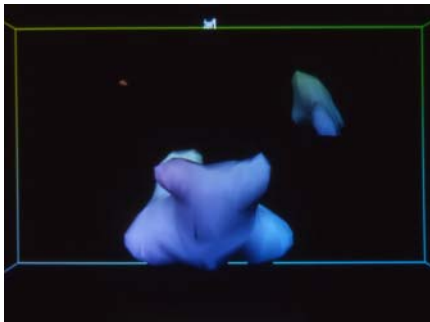
- 6 month old girl; 4 months after 2 episodes of trauma by father (repetitive slamming on crib bed (resolved), 3 days later severe trauma with cardiac arrest).
- Problems indicated at initiation of HBOT:
  - Never smiled. No social interaction.
  - Minimum ability to eat.
  - Paraplegia.
  - Seizures; hand and arm twitching many times per day for 45 seconds each.
    - 1<sup>st</sup> scan: baseline SPECT: Minimal brain blood flow to higher centers of brain.
- 80 HBOT treatments.
  - Starting to smile, positive social interaction with mother.
  - Eating baby food.
  - Significant improvement in use of hands and arms.
  - Calmer.
  - No seizures while off nearly all seizure medication.
    - 2<sup>nd</sup> scan: SPECT image shows improved brain blood flow to higher centers.
- Example of savings: Nursing care costs reduced and prescription drug cost alone was reduced by at least \$500/year with increased savings each year of additional life.

LHE May 02, 2002  
Copyright Retained  
Paul G. Harch, M.D. 2002




# Case Presentation

## *Shaken Baby* *6 month female*



Scan #1



Scan #2

LHE May 02, 2002  
Copyright Retained  
Paul G. Harch, M.D. 2002



# Case Presentation

## *Gun Shot Wound to Brain*

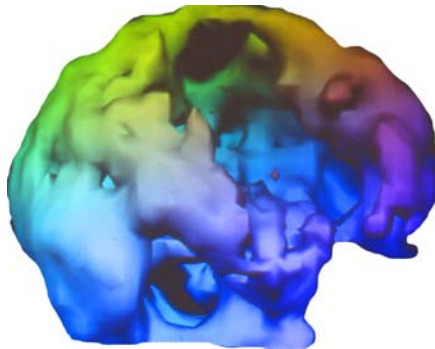
- 29 year old female; self-inflicted .38 caliber hollow point to right temple.
- 6 years post trauma:
  - Severe spasticity arms and legs.
  - Paraplegia with severe weakness in arms.
  - Poor trunk control.
  - Insomnia secondary to muscle spasms.
  - Intractable constipation.
  - Headaches.
- 1<sup>st</sup> scan: baseline SPECT: Marked diffuse decrease in blood flow with worst area along path of bullet.
- 80 HBOT treatments.
  - Physiatrist reports: Generalized decrease in spasticity, increase in left hand grip, and movement in knees.
  - Patient reports:
    - Increased trunk and extremity motor function.
    - Marked decrease in insomnia.
    - Natural bowel movements without constipation.
    - Decreased headaches.
- 2<sup>nd</sup> scan: Generalized increase in brain blood flow with pattern of diffuse smoothing.

LHE May 02, 2002  
Copyright Retained  
Paul G. Harch, M.D. 2002



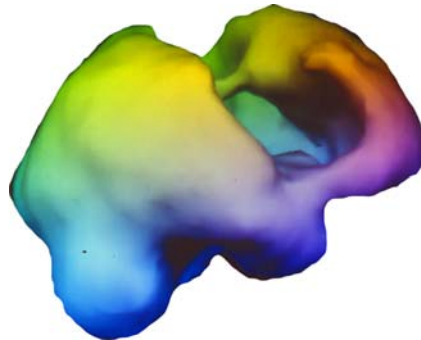
# Case Presentation

## *Gun Shot Wound to Brain* *29 y. female*



Scan #1

right view



Scan #2

LHE May 02, 2002  
Copyright Retained  
Paul G. Harch, M.D. 2002





# Case Presentation

## Autism

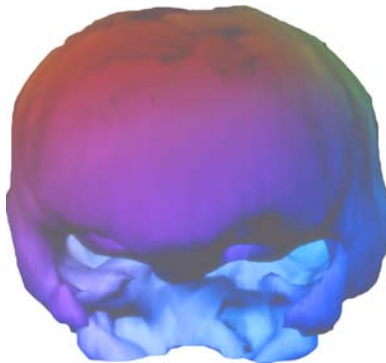
- 3 year old female born 3 weeks premature to a mother with mild toxemia; fetal distress, emergency C-section. Extensive neurological workup over the next year.
- Final diagnoses: Persistent Developmental Delay/Autism/Mild, Mental Retardation.
  - Can't talk or walk (walks on knees).
  - Minimum eye contact.
  - Afraid of crowds and people.
  - No self-help.
  - Self-abusive behavior.
  - 1<sup>st</sup> scan: Marked reduction in blood flow to temporal lobes, less so to cerebral lobes.
- 80 HBOT treatments.
  - Walks with a walker.
  - Makes eye contact and is interactive and playful.
  - Comfortable in crowds and with people.
  - Feeds self.
  - Decreased self-abusive behavior.
  - 2<sup>nd</sup> scan: Marked improvement in blood flow to temporal and cerebral lobes. Generalized increase to rest of brain.
- 7 months later: Continued generalized improvement.
  - Full ambulation.
  - Playful, interactive, affectionate, loving.
  - Self-abusive behavior nearly gone.

LHE May 02, 2002  
Copyright Retained  
Paul G. Harch, M.D. 2002

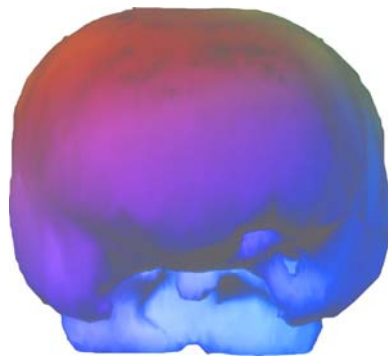


# Case Presentation

## Autism 3 y. female



Scan #1



Scan #2

LHE May 02, 2002  
Copyright Retained  
Paul G. Harch, M.D. 2002



# Case Presentation

## *Traumatic Brain Injury from Child Abuse*

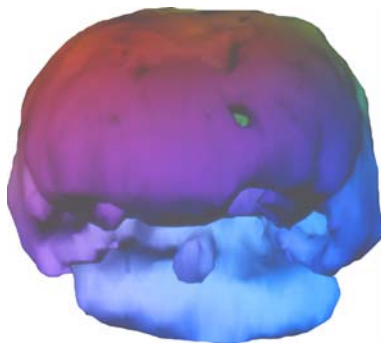
- 48 year old male. 45 years post injury; extensive physical damage to right parietal bone at age 3.
- Apparently normal motor coordination.
- Difficulty with higher math and remembering names.
- Dreamed in black and white.
  - 1<sup>st</sup> scan: Before
- 63 HBOT treatments.
  - 2<sup>nd</sup> scan: After
- Improved motor coordination, math skills, and name memory.
  - Now dreams in color.

LHE May 02, 2002  
Copyright Retained  
Paul G. Harch, M.D. 2002

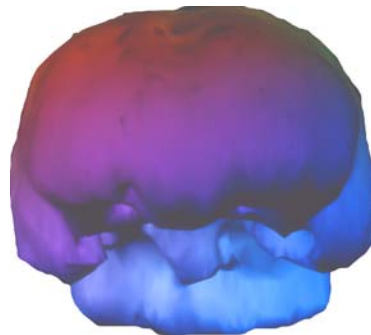


# Case Presentation

## *Traumatic Brain Injury from Child Abuse* *48 y. male*



Scan #1



Scan #2

LHE May 02, 2002  
Copyright Retained  
Paul G. Harch, M.D. 2002



**Dr. Harch's cost-effective, refined low-pressure Hyperbaric Oxygen Therapy protocols have improved the quality of life for 1,000's of brain and neurologically injured patients. Treatment is here today!**

**Dr. Harch's success has been replicated by physicians in multiple treatment centers throughout the United States and many other countries around the world.**

For a treatment center near you please visit  
[www.hbonetoday.com/ihma/ih.html](http://www.hbonetoday.com/ihma/ih.html)  
or call Ken Locklear, Executive Director of IHMA, at 561-640-4546.

For further technical information please visit  
[www.hyperbarics.org](http://www.hyperbarics.org)  
or call Dr. Paul Harch, President of IHMA, at 504-348-1660.